



## Case Study

# Idiopathic Gingival Enlargement Associated With Chronic Periodontitis: A Case Report

Tripathi Amitandra K<sup>1,\*</sup>, Khan Mohammad Arif<sup>1</sup>, Jaishwal Rajeev K<sup>1</sup>, Kaur Jaspreet<sup>2</sup>, Agrawal Ankit<sup>3</sup>

<sup>1</sup> Department of Periodontology, Career Postgraduate Institute of Dental Sciences and Hospital, Lucknow, Uttar Pradesh, India.

<sup>2</sup> Maharshi Markandeshwar dental college Mullana, Ambala, India.

<sup>3</sup> Institute of dental sciences and technology, Modinagar, India.

### ARTICLE INFO

Received: 22 May 2015  
Accepted: 19 Jun 2015

### A B S T R A C T

Idiopathic gingival enlargement (IGF) is a rare condition characterized by massive enlargement of the gingiva. It can be an isolated entity or may be associated with syndrome, but rarely associated with periodontitis. In this present case a 30 years old male reported with chief complaint of swollen and bleeding gums, slowly progressive gingival enlargement since last 3 years, with esthetic deformities and difficulty in mastication. Clinical examination revealed diffuse gingival enlargement with generalized periodontal pockets. Radiograph showed generalized moderate to severe alveolar bone loss. Lesion was surgically removed after meticulous scaling and root planing. Post operative healing was satisfactory with significant improvement in esthetic and mastication. There was no post operative recurrence during 2 years of follow-up.

**Keywords:** Idiopathic, periodontitis, deformities, mastication.

## 1. INTRODUCTION

Idiopathic gingival enlargement is a rare condition, characterized by slow, progressive gingival enlargement with on specific cause. In this condition mode of inheritance may be an autosomal-dominant or recessive.<sup>1,2</sup>

This condition gingiva is pink in color, firm in consistency, with abundant stippling, and has a characteristic pebbled surface which affects the

### Corresponding author \*

Dr Amitandra kumar Tripathi  
16/29 Sohbatibagh, Allahabad, India

marginal gingiva, attached gingiva and interdental papilla.<sup>1</sup>

Histopathologically idiopathic gingival enlargement is characterized by densely arranged collagen-fibre bundles, numerous fibroblasts and mild chronic inflammatory cells.<sup>3</sup>

## 2. CASE REPORT

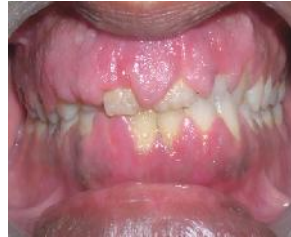In present case a 30 year old male reported with complaint of swollen gums since last 3 years with poor esthetics and masticatory problems. There was no history of drug treatment. His current health condition and mental status was normal. He revealed that none of his family members were affected with any form of gingival enlargement.

Intra oral examination revealed massive, generalised diffuse type of gingival enlargement involving the both the arches.[fig.1] Gingiva was pale pink, firm consistency with pebbled surfaces and heavy dental plaque and subgingival calculus and generalised periodontal pocket range 5 to 8 m.m. with mobility in some teeth. Panoramic radiograph shows that generalized alveolar bone loss.[fig.2] Histopathological investigations of the excised tissue revealed atrophic parakeratinized stratified squamous epithelium with the dense avascular fibrocollagenous tissue.[fig.3]

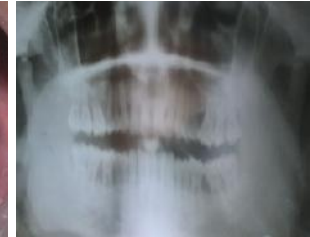Severity of gingival enlargement was not related with the amount of local factors present and the presence of local factors might be secondary to gingival enlargement because a massive gingival enlargement interferes to maintain proper oral hygiene by the patient. Considering the severity of the enlargement, a quadrant-by-quadrant internal bevel gingivectomy plus full thickness mucoperiosteal flap surgery was chosen as the preferred surgical technique after scaling and root planing.[fig.4]

Post operative healing was satisfactory and desired crown lengthening was achieved. Patient's esthetic and masticatory problems were completely resolved with

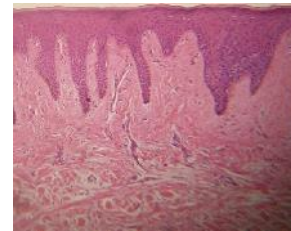
gain of adequate functional ability. Esthetics was significantly improved in terms of gingival appearance after surgical excision of enlarged gingival tissue. Patient was put in follow-up programme at 1, 3, 6 months interval followed by after 1 and 2 years. There was no recurrence of the disease even after two years follow up.[fig.5]



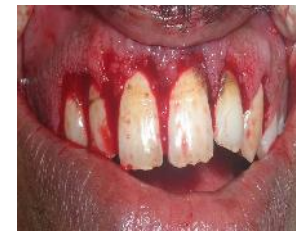**Fig 1: Preoperative view**



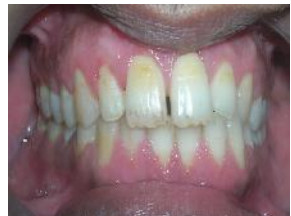**Fig 2: Orthopantomogram of patient showing loss of alveolar bone**



**Fig 3: Histopathological specimen showing stratified squamous epithelium with long slender rete pegs, connective tissue and dense collagen stroma**



**Fig 4: Intra-operative view**



**Fig 5: Post-operative 2 years**

## 3. DISCUSSION

Massive gingival enlargement is usually associated with various drugs treatment, syndromes, and hereditary disorders.<sup>4, 5</sup> There are very few case of idiopathic gingival enlargement associated with periodontitis. The present report describes a case of idiopathic gingival enlargement with chronic periodontitis.

Clinically and histologically it is difficult to differentiation between idiopathic, hereditary, and drug induced gingival enlargement is difficult. In the present

case diagnosis of idiopathic gingival enlargement with chronic periodontitis was made, because the enlargement was not related to hereditary, syndromes, drugs, conditions, or endocrine problems. The presence of thick band of sub gingival calculus, deep periodontal pockets, mobility and negative family history for periodontal disease supports the diagnosis of chronic periodontitis and histological finding of the surgically removed tissue supports the diagnosis of idiopathic gingival enlargement. Severity of gingival enlargement was not related with the amount of local factors present and the presence of local factors might be secondary to gingival enlargement which interferes in proper oral hygiene maintenance by the patient.

Various types of treatment modalities have been employed for the excision of the enlarged gingival tissues, including of conventional surgery, electro surgery, an apically positioned flap and lasers.<sup>6</sup> Use of conventional surgical intervention means like scalpel may sometimes be technically difficult and impractical some cases such as in children or mentally handicapped, or in patients suffering from impaired haemostasis, so in such situation use of electro surgery would be beneficial approach because they minimize the bleeding and simultaneously reduce the bulk of the tissues. In the present case internal bevel gingivectomy plus full thickness mucoperiosteal flap technique was performed because of the severity of gingival enlargement and the presence of deep periodontal pockets. A periodontal flap procedure may be preferred for the treatment of gingival enlargement if there are large areas of gingival overgrowth or attachment loss and osseous defects.<sup>7</sup>

Reports about recurrence rates are contradictory<sup>8</sup> so the post-operative long-term benefit of periodontal surgery cannot be predicted. Some reports in severe cases of hereditary gingival fibromatosis, full-mouth tooth clearance has been advocated and they suggest

that the condition does not recur if the teeth have been extracted.<sup>8, 9</sup> One report indicated that there is less chance of recurrence if the gingivectomy is delayed until the permanent dentition is in place.<sup>10</sup> In our case report there was no recurrence of the disease even after two years follow up

#### 4. REFERENCES

1. Bozzo L, de Almedia OP et.al .Hereditary gingival fibromatosis. Report of an extensive four-generation pedigree. *Oral Surg Oral Med Oral Pathol* 1994; 78(4):452-4.
2. Jorgenson RJ, Cocker EM. Variation in the inheritance and expression of gingival fibromatosis. *J Periodontol* 1974; 45(7):472-7.
3. Collan Y, Ranta H et.al. Histochemical and biochemical study of hereditary fibrous hyperplasia of the gingiva. *Scand J Dent Res*.1982; 90:20-8.
4. Bittencourt LP, Campos V et.al. Hereditary gingival fibromatosis: Review of the literature and a case report. *Quintessence Int*. 2000; 31:415-8.
5. Thomas D, Rapley J et.al. Tuberos scleriosis with gingival overgrowth. *J Periodontol*. 1992; 63:713-7.
6. Howe LC, Palmer RM. Periodontal and restorative treatment in a patient with familial gingival fibromatosis: A case report. *Quintessence Int*. 1991; 22:871-2.
7. Girish P, Nagarale, S, Ravindra. Long term follow up of idiopathic gingival enlargement associated with chronic periodontitis: A case report and review
8. Danesh-Meyer MJ, Holborow DW. Familial gingival fibromatosis: A report of two patients. *N Z Dent J*. 1993; 89:119-22.
9. Kharbanda P, Sidhu SS, Panda SK, Deshmukh R. Gingival fibromatosis: Study of three generations

- with consanguinity. Quintessence Int. 1993; 24: 161-4.
10. James PL, Prasad SV. Gingival fibromatosis: report of a case. J Oral Surg 1971; 29(1):55-9.

**Conflict of Interest: None**

**Source of Funding Nil**