



Case Study

An Unusual “Near Miss” Case from an Underdeveloped North-Eastern Region of India

Maureen P Tigga^{*}, Salil B Chakrabarti

Department of obstetrics and gynecology, Agartala Government Medical College & GB Pant Hospital, Agartala, Tripura, India.

ARTICLE INFO

ABSTRACT

Received: 07 Jul 2015
Accepted: 17 Aug 2015

Maternal morbidity due to intestinal obstruction secondary to a silent obstetric cause is very uncommon. Such cases are often difficult to diagnose due to the non specific symptoms and further when they emerge from areas served by the rural health centre. Delay in approaching the health system is another cause for deterioration of the patient who often present as a near miss case to the tertiary centre. Reported here is a case of woman who presented with intestinal obstruction during puerperium but laparotomy revealed an interesting clinical situation.

Keywords: Intestinal obstruction, Puerperium, Near miss

1. INTRODUCTION

Intestinal obstruction (IO) during pregnancy is rare and its incidence is estimated at 1:1500-1:66431 pregnancies.¹ Mostly it is diagnosed in second and third trimester but can also present during first trimester and puerperium. During pregnancy the most common causes are: adhesions (54.6%), intestinal torsion (25%), colorectal carcinoma (3.7%), hernia (1.4%), appendicitis (0.5%) and others (10%). Obstruction due to adhesions is more frequent during advanced pregnancy (6% - 1st trimester 28% - 2nd trimester; 45% - 3rd trimester & 21% - puerperium).¹

Corresponding author *

Dr. Maureen P. Tigga, MBBS, MS. Senior Resident,
Department of Obstetrics & Gynaecology, Agartala Government
Medical College & GB Pant Hospital, Agartala, Tripura, India.
Email: maurentigga@gmail.com
Contact no. +91 9818405203

The presenting symptoms can vary from crampy abdominal pain associated with vomiting to a state of shock leading to severe morbidity like a near miss² case or even mortality. Here is a case of a P5L5 woman who had delivered 20 days back and reported to our emergency unit in a state of shock.

2. CASE REPORT

A 36 year old woman, hailing from the rural interiors of Tripura, a northeastern region in India, presented to our hospital in a state of shock. She was parity 5 with 5 living children all delivered vaginally. Historian was the patient's husband who revealed that her last child birth was 20 days back in a rural health centre and she was discharged 48 hours following her delivery without any complaints. On 18th postpartum day she was seized with severe abdominal pain associated with bilious vomiting and she subsequently presented to us after two days in a severely morbid state. On examination severe pallor and temperature 101° F were noted. Her pulse rate was 120/ min and the blood pressure was 80/60 mmHg. Abdomen was distended and bowel sounds were absent. An emergency bedside ultrasound showed free fluid and dilated bowel loops. Her other investigations were: Hemoglobin 5.6 gm%, WBC count 17,300/mm³, X- ray abdomen in supine and erect position demonstrated small bowel distention and with definite fluid levels. Diagnosis of small bowel obstruction was made and emergency laparotomy was conducted. Per operative findings showed hemoperitoneum of 500ml with dilated small bowel loops adherent to the anterior uterine wall. On relieving the adhesions a 3x3 cm rent was seen on the uterus which was subsequently repaired. Patient was transfused 4 units of blood and she stood the procedure well. Looking at this unusual presentation of silent uterine rupture, a detailed history of labour events was extracted from the patient postoperatively who was now fit to be the source of information herself. She

revealed that her labour was protracted and she delivered a male baby of 3.5 kilograms. She also narrated that she had a delayed episode of postpartum hemorrhage probably due to retained bits of placenta for which she underwent some minor procedure at the rural health centre. She was discharged 48 hours after this episode with no apparent morbidity.

3. DISCUSSION

It is an intriguing situation when the manifestation of an unexpected underlying obstetric etiology is in the form of IO, because it is a rare event during pregnancy and puerperium. Similar clinical scenario occurred in our case which was a maternal near miss², where silent rupture of an unscarred uterus presented as the same. Rupture of the unscarred pregnant uterus itself is a rarity and is estimated to occur in 1/5700 to 1/20,000 pregnancies.³⁻⁵ Pathogenesis of rupture of the unscarred uterus is not defined with certainty. It has been attributed to inherent or acquired myometrial weakness, collagen matrix disorders (Ehlers-Danlos type IV),^{6, 7} and abnormal architecture of the uterine cavity (bicornuate uterus, uterus didelphys, blind uterine horn)⁸. Over distension of the uterus is another major physical factor associated with rupture in such cases.⁵ Diagnostic dilemma arises when the patient remains asymptomatic or presents with non specific symptoms like vague abdominal pain for many days. Further, lack of resources and expertise in the rural areas add more to the predicament.

Our case was quite unusual because both the aforementioned rare entities presented in the same patient. The cause of silent rupture was attributed to uterine overdistension, as she was a grand multipara and delivered a good sized baby. Moreover there was history of protracted labour along with a delayed episode of post partum hemorrhage for which some minor procedure was done. As the patient could not specify the exact nature of intervention done the actual

cause of uterine rupture could not be delineated in our case. The rupture caused no major morbidity in the patient and went undetected and silent for more than a fortnight postpartum. This was a surprising situation. Features of IO developed after bowel loops got adhered to the uterine rent. A perplexing clinical situation was confronted when our patient presented as a surgical emergency and the unexpected obstetrical cause was unmasked during laparotomy.

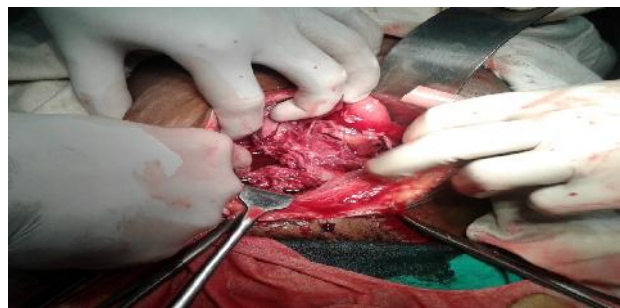


Fig 1: Clinical photograph showing dilated bowel loop with the underlying anterior wall uterine rent.

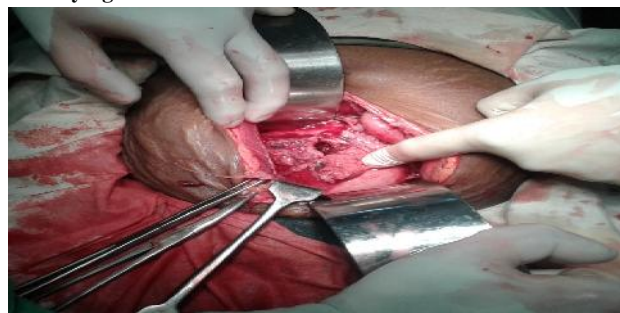


Fig 2: Clinical photograph showing the uterine rent after clearing bowel adhesions and few sutures of repair.

4. CONCLUSION

Intestinal obstruction during puerperium due to rupture of an unscarred uterus is an exceptional presentation. Awareness about such rare cases helps us to broaden our clinical insights.

5. REFERENCES

1. Stukan M, Kruszewski Wiesław J, Dudziak M, Kopiej A, Preis K. Intestinal obstruction during pregnancy. *Ginekol Pol.* 2013 Feb;84(2):137-41.
2. Geller SE, Rosenberg D, Cox SM, Kilpatrick S. Defining a conceptual framework for near-miss maternal morbidity. *J Am Med Womens Assoc.* 2002 Summer;57(3):135-9.

3. Dow M, Wax JR, Pinette MG, Blackstone J, Cartin A. Third-trimester uterine rupture without previous cesarean: a case series and review of the literature. *Am J Perinatol.* 2009 Nov; 26(10):739-44.
4. Porreco RP, Clark SL, Belfort MA, Dildy GA, Meyers JA. The changing specter of uterine rupture. *Am J Obstet Gynecol.* 2009 Mar;200(3):269
5. Garg N, Grover S, Aggarwal S. Silent uterine rupture of unscarred uterus- an unusual presentation. *Int J Med Res Health Sci.* 2015;4(2):460-463.
6. Taylor DJ, Wilcox I, Russell JK. Ehlers-Danlos syndrome during pregnancy: a case report and review of the literature. *Obstet Gynecol Surv.* 1981 Jun;36(6):277-81.
7. Jones DE, Mitler LK. Rupture of a gravid bicornuate uterus in a primigravida associated with clostridial and bacteroides infection. *J Reprod Med.* 1978 Sep; 21(3):185-8.
8. Samuels TA1, Awonuga A. Second-trimester rudimentary uterine horn pregnancy: rupture after labor induction with misoprostol. *Obstet Gynecol.* 2005 Nov; 106 (5 Pt 2):1160-2.

Conflict of Interest: None

Source of Funding Nil