



Original Article

Morphological Study of Sulci and Gyri of Occipital Lobe of Cerebral Hemisphere of Human Brain

Gindha Gurbachan Singh^{1,*}, Kaushal Subhash², Patnaik VV Gopichand³, Chhabra Usha⁴

¹ Professor, Department of Anatomy, Government Medical College and Hospital, Patiala, India.

^{2,4} Professor, Government Medical College Patiala, India.

³ Professor, Maharishi Markandeshwar University, Mullana, India.

ARTICLE INFO

ABSTRACT

Received: 02 Nov 2016
Accepted: 17 Dec 2016

The occipital lobe of the cerebral hemisphere of human brain is a conical lobe which lies behind the parieto-occipital sulcus on its medial surface, and posterior to an imaginary line drawn on the superolateral surface of the occipital lobe, in between the parieto-occipital sulcus and pre-occipital notch present on the infero-lateral border of the occipital lobe. The occipital lobe is having many sulci and gyri on its all the three surfaces. Out of all the sulci present on the surfaces of occipital lobe the calcarine and lunate sulci are important because the visual cortical area lies around these sulci. The present study is done on (60) cerebral hemispheres of (30) human cadavers which were embalmed and fixed with (10%) formaldehyde. The arachnoid matter and blood vessels were removed by taking care that no tearing occurs to the brain tissue. In the present study the variations found in the lunate, the transverse occipital, superior and inferior polar sulci. The lunate sulci were found present in occipital lobes of cerebral hemispheres in 26 (86.7%) cases, 12 (40%) on right occipital lobes and 14 (46.7%) on left occipital lobes. The variations found in the lunate sulci were asymmetrical. The transverse occipital sulci were present in all 30 (100%) in occipital lobes of right cerebral hemispheres but these were present in 26 (86.7%) cases of occipital lobes of left cerebral hemispheres. These sulci were absent in 4 (13.3%) cases of left occipital lobes. The superior and inferior polar sulci were present in 12 (40%) cases in right occipital lobes and in 14 (46.7%) cases in left occipital lobes of cerebral hemispheres of the brains. The present study is compared with the standard literature and studies done by other workers. The anatomical knowledge of presence of sulci and gyri on the occipital lobe of cerebral hemispheres of human brain is important for anatomists, neurosurgeons and general surgeons while operating on the posterior lobe surgery in case of tumors and accidental injuries.

Key words: Morphology, calcarine sulcus, lunate sulcus, parieto-occipital sulcus, lateral occipital sulcus, transverse occipital sulcus, superolateral surface, tentorial surface, cuneus gyrus, lingual gyrus, neurosurgery, occipital groove.

1. INTRODUCTION

The occipital lobe of cerebral hemisphere of human brain is the posterior lobe of the brain which lies in the posterior cranial fossa of the skull. It is separated from other lobes of brain by an imaginary line drawn in between the parieto-occipital sulcus and pre-occipital notch on the infero-lateral

Corresponding author *
Dr. Gurbachan Singh Gindha,
46-Kamal Colony,
Street no. 2,
Sirhind Road,
Patiala, Punjab (India)
Email: drgindhags@yahoo.com

border of the cerebral hemisphere and posterior to the parieto-occipital sulcus on the medial surface. The medial surface of the occipital lobe is having a wedge shaped structure which is called as the cuneus. The cuneus is limited inferiorly by the calcarine sulcus which runs from the occipital pole to the medial surface of the temporal lobe. The parieto-occipital sulcus runs into it and the parieto-occipital and calcarine sulci form a pattern like the letter-Y on its side; the common stem of the Y is the anterior part of the calcarine sulcus, and the two limbs are the parieto-occipital sulcus and the posterior part of the calcarine sulcus. The lingual gyrus lies below the posterior part of the calcarine sulcus and is limited at the borders between the medial and inferior surfaces of the occipital lobe by the collateral sulcus. On the inferior surface of the occipital lobe two long parallel sulci i.e. the occipito-temporal sulcus laterally and the collateral sulcus lies on the medial. They run anteroposteriorly between the temporal and occipital poles. Medial to the collateral sulcus is the para-hippocampal gyrus (Strandinger-2008¹, Sinnatamby -2011²).

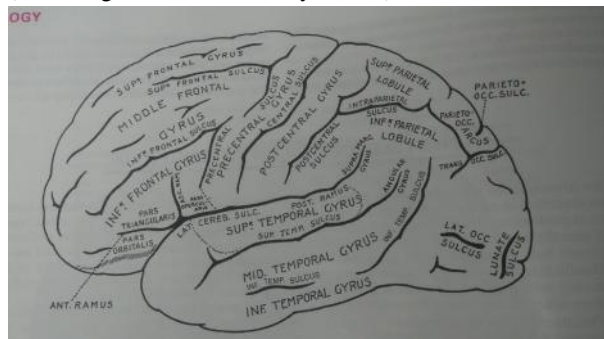


Fig 1: Superolateral surface of left cerebral hemisphere of human brain (With thanks taken from Gray's Anatomy 37th Edition, 1989)

The sulci on the occipital lobe of cerebral hemisphere of human brain were the subject of study for brain anatomists for many years and much discussion arose regarding homologies, resulting in a rather extensive literature. Smith (1903)³ introduced the term sulcus lunatus to designate the furrow which bounds anteriorly the visual or striate area on the lateral surface of the occipital lobe. He defined the sulcus lunatus as "a depression formed by the forward projection of the cortical area containing the stria of Gennari (Connolly – 1950)⁴.

The superolateral surface of the occipital lobe is marked by several occipital gyri. The medial surface contains the cuneus (wedge shaped) between the parieto-occipital sulcus and the important calcarine sulcus. The inferior surface shows three gyri and three sulci. The Lateral and medial occipito-temporal gyri are separated by the occipito-temporal sulcus. The lingual gyrus lies between the collateral sulcus and the anterior end of the calcarine sulcus (FitzGerald et al-2012⁵; Snell-2010⁶).

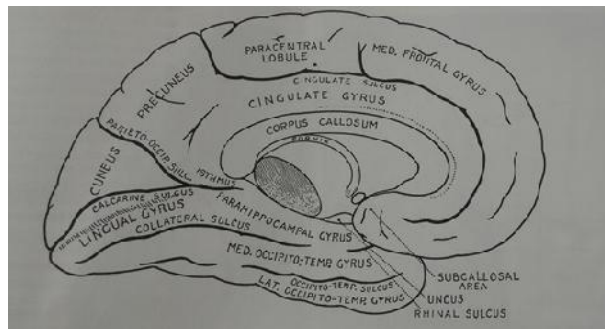


Fig 2: Medial and inferior surface of left cerebral hemisphere of human brain (With thanks taken from Gray's Anatomy 37th Edition, 1989)

Romans-(1995)⁷ described that the lunate lies on end of calcarine, lateral occipital, transverse occipital, parieto-occipital and intraparietal sulci are present on the superolateral surface of cerebral hemispheres of human brain. On the medial surface the parieto-occipital, calcarine, posterior end of the collateral, occipito-temporal, and cuneus sulci are present. Whereas on the inferior surface of occipital lobe the occipito-temporal, collateral and the lingual sulci are present. The gyri arcus parieto-occipitalis, inferior temporal gyri on the superolateral surface, and the cuneus, lingual, medial occipito-temporal, occipito-temporal gyri are present on the medial surface. On the inferior surface lateral occipito-temporal gyrus is present. The gyrus descendens intervenes between the lunate sulcus and the superior and inferior occipital gyri. Sometimes the superior and inferior polar sulci extend in arched manner from the two ends of the lunate sulcus. The polar and lunate sulci delimit the striate area which receives projections fibres from the macular part of the retina through the lateral geniculate body (Dutta-2009)⁸.

The morphological variations of the sulci of occipital lobes of the human brains were examined by (Iaria and Petrides-2007)⁹ and described that in the medial occipital region, the calcarine sulcus was the longest and most constant sulcus, in the inferior part of the medial occipital lobe, the lingual sulcus and the posterior collateral sulcus, and in superior part, the inferior and superior sagittal sulci of the cuneus. On the lateral surface of the occipital lobe, the lateral occipital, the lunate and the transverse and inferior occipital sulci were identified. The parieto-occipital fissure and the Temporo-occipital incisures were also identified on the lateral and medial surface.

Allen et al. (2006)¹⁰ described that the presence of the lunate sulcus on the occipital lobe was variable. The presence of lunate sulcus in the right and the left cerebral hemispheres were in the frequency of 26.4% and 32.7% respectively. They found that in vast majority of cases, lunate sulci identified on the surface of the occipital lobe, are actually composed of smaller sulcal segments that converge into an apparently continuous composite lunate sulcus. The composite lunate sulci were found in 32.7% of left cerebral hemisphere and 26.4% of right cerebral hemisphere. Ono et

al. (1990)¹¹ described that the lunate sulcus was present in 60% of the right and 64% of the left hemisphere.

According to Ananth (1998)¹² the post calcarine sulcus terminates at the occipital poles in 73 out of 99 sides i.e. (73.74%) of cases. The position of the lunate sulcus marks the posterior end of the calcarine sulcus (Velmurugan et al. 1990)¹³. Joshi et al. (2014)¹⁴ described in their study that the calcarine sulcus did not reach the occipital pole in 8 specimens (24.1%) and hence was not limited by the lunate sulcus on the superolateral surface.

Falk's (1978)¹⁵ described that the sutures are readily distinguished from sulci on endocasts (Falk-1980)¹⁶, since sulci are represented by grooves and sutures are represented by protruding line that often look like sutures. Dart (1956)¹⁷ and Broom and Schepers (1946)¹⁸ identified the lunate sulcus and defined it as the lambdoid suture, and also suggested by Clark et al. (1936)¹⁹.

Flores (2002)²⁰ wrote in his research paper that the occipital lobe is an important region of the central nervous system, which is responsible for the sense of vision. It is a posterior extension of the parietal lobe, arbitrarily divided due to its unique function and to facilitate research and studies on this region. The imposed limits give to the occipital lobe a triangular shape, delineated on the medial surface by the parieto-occipital sulcus; on the lateral surface by an imaginary line connecting the end of the parieto-occipital sulcus to the pre-occipital notch labeled parieto-temporal lateral line; and the inferior surface (tentorial) by anterior line that connects the pre-occipital notch to the beginning of the parieto-occipital sulcus (where it emerges from the calcarine sulcus) labeled parieto-temporal basal line (Carpenter- 1991²¹, Ono et al.- 1990¹¹). On its medial surface, there is cuneus, (a gyrus) is located in between the calcarine sulcus and the parieto-occipital sulcus. Inferior to the calcarine sulcus in the tentorial surface of the lobe, there is lingual gyrus. The collateral sulcus separates the lingual gyrus from the fusiform gyrus. Among the transverse sulci, the most frequently cited sulci are the transverse occipitalis and the lateral occipital sulci. The sulci of the lateral surface as the inferior and superior occipital were described by (Ono et al. 1990¹¹; Seeger -1978²²).

According to Ribas (2010)²³ on the medial surface of the cerebral hemisphere the occipital lobes is delineated and characterized by its well defined and anatomically constant sulci and gyri. Its principal sulcus is the calcarine sulcus, which is located just above the inferomedial margin of the cerebral hemisphere. The inferior surface of the occipital lobe, in turn, is continuous with the basal surface of the temporal lobe. The medial surface of cerebral hemisphere is having the calcarine, parieto-occipital and collateral sulci, whereas the gyri are cuneus and lingual. The superolateral surface is having the superior occipital, transverse occipital, inferior occipital and lateral occipital sulci, the middle occipital and inferior occipital gyri. The lunate sulcus is typically oriented vertically, immediately facing the occipital

pole. The gyrification patterns are a function of relative cortical expansion and relative thickness and are consistent with observations of a wide range of brains, ranging from smooth to highly convoluted. The brain also allows us to qualitatively explain how variations in these parameters lead to anatomical anomalies in such situations as polymicrogyria, pachygyria and lissencephalia (Tallinen et al. 2014)²⁴.

On the surfaces of the occipital lobes of cerebral hemispheres the sulci and gyri are very constant. If the post calcarine sulcus of the medial surface extends into this surface it carries a part of the center for sight with it, and the center is then bounded by a curved sulcus called the sulcus lunatus. The sulci present on the medial surface of occipital lobe of cerebral hemisphere are the parieto-occipital, calcarine and post-calcarine and the gyri present on the medial surface are the gyrus lingualis, cuneus and pre-cuneus. The gyrus lingualis is the area below the calcarine and post-calcarine sulci. It separates them from the posterior part of the collateral sulcus, and forms part of the tentorial surface as well as the medial surface. The cuneus is the wedge enclosed by the post-calcarine and the parieto-occipital sulci and the supero-medial margin. It also contains a part of the center for sight (Brash – 1960)²⁵.

Chusid (1967)²⁶ wrote that calcarine fissure divides the medial surface of the occipital lobe of cerebral hemisphere into the cuneus and lingual gyri. In the occipital region a small but somewhat variable sulcus merits attention because of its relation to the visual cortex. This is called the lunate sulcus. It is situated close to the occipital pole and forms the anterior boundary of the limited part of the visual cortex which extends on to the lateral surface of the cerebral hemisphere (Hamilton – 1976)²⁷.

In the human brains the calcarine sulcus continuous for a short distance over the occipital pole. There is a curved lunate sulcus around the end of the calcarine sulcus. Except for this inconstant marking the small area of the occipital lobe on the lateral surface has minor grooves and folds of no special significance. The sulci and gyri serve only a rough frame of reference for cortical area whose functions may or may not be known (Kiernan - 1998)²⁸.

The lunate sulcus, when present, lies just in front of the occipital pole. The lunate sulcus is posterior to the gyrus descendens, which is behind the superior and inferior occipital gyri. Curved superior and inferior polar sulci often appear near the ends of the lunate sulcus. The superior polar sulcus arches up on to the medial occipital surface near the upper limit of the lunate sulcus. The inferior polar sulcus arches down and forward onto the inferior cerebral surface from the lower limit of the lunate sulcus. These polar sulci enclose semilunar extensions of the striate area, and indicate the extent of the visual cortex associated with the macula (Standring – 2005)¹. The lunate sulcus, when present, is situated close to the occipital pole. It is a short, curved sulcus, having its concavity directed backwards. Posterior to it, a small part of the calcarine sulcus may cut across the

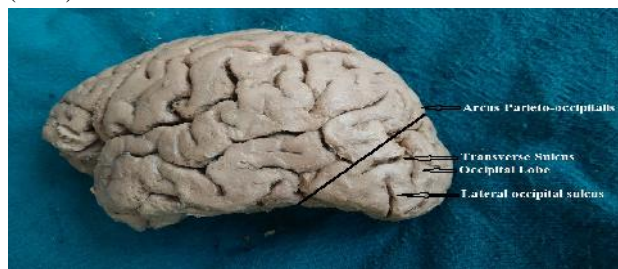
Int J Pharma Res Health Sci. 2016; 4 (6): 1454-1461
occipital pole and appear on the superolateral surface of the hemisphere of the brains (Jones – 1942)²⁹.

2. MATERIAL AND METHODS

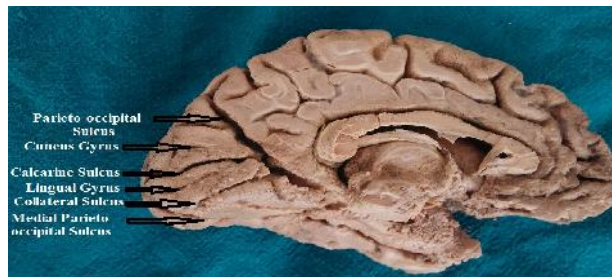
The present study has been conducted on 30 embalmed cadaveric human brains which were collected from the Department of Anatomy of Government Medical College Patiala, India, after routine dissection of the cadavers. The brains were preserved in 10% formalin for the study. The brains were washed with running water and removed the arachnoid mater and blood vessels from the brains by taking care that there should be no tearing of the brain substance along with the meninges and blood vessels. Again washed the brains under running water. Demarcated the occipital lobes of the cerebral hemispheres according to Cunningham’s Manual of Practical Anatomy (Romans - 2012)³⁰ and studied the various sulci and gyri of the all the three surfaces of the occipital lobes of 60 (30 right and 30 left) cerebral hemispheres of the 30 human brains according to the description given by Williams et al. (1989)³¹. All the three surfaces of occipital lobes were photographed and the sulci and gyri recorded in tabulated form. The sulci and gyri found during the study were compared with the standard literature and studies done by other authors.

3. OBSERVATIONS

The present study has been concluded on prefixed 30 human brains, in the Department of Anatomy of Government Medical Collage Patiala, India. 60 occipital lobes of cerebral hemispheres of 30 human brains which were fixed with 10% Formaldehyde, were studied for the presence of the various sulci and gyri on all the three surfaces of the occipital lobes of the human brains. The sulci and gyri were studied according to the description given by Williams et al. (1989)³¹.



(Photograph I) Superolateral surface of left cerebral hemisphere of human brain



(Photograph – II) Medial and inferior surfaces of left cerebral hemisphere of human brain

Table 1: Sulci found on the superolateral surface

Type of sulci	Right Occipital lobe		Left Occipital lobe	
	No. of cases found	% age	No. of cases found	% age
Parieto-occipital	30	100	30	100
Lateral occipital	30	100	30	100
Lunate	12	40	14	46.7
Transverse occipital	30	100	26	86.7
Superior polar	12	40	14	46.7
Inferior polar	12	40	14	46.7

Table 2: Sulci found on the medial surface

Type of sulci	Right Occipital lobe		Left Occipital lobe	
	No. of cases found	% age	No. of cases found	% age
Parieto-occipital	30	100	30	100
Calcarine	30	100	30	100

Table 3: Sulci found on the inferior surface

Type of sulci	Right Occipital lobe		Left Occipital lobe	
	No. of cases found	% age	No. of cases found	% age
Collateral	30	100	30	100
Occipito-temporal	30	100	30	100

Table 4: Gyri found on the superolateral surface

Type of Gyri	Right Occipital lobe		Left Occipital lobe	
	No. of cases found	% age	No. of cases found	% age
Arcus Parieto-occipitalis	28	93.3	28	93.3
Superior occipital	30	100	30	100
Inferior occipital	30	100	30	100
Gyrus descendens	12	40	14	46.7

The present study which is concluded on prefixed 30 human brains (30 right and 30 left) cerebral hemispheres). On the superolateral surfaces, lateral occipital, parieto-occipital, calcarine and occipito-temporal sulci were present in all the occipital lobes of cerebral hemispheres of the brains i.e. (100%) present in all the cases of brains, with slight variations like shape and size. The variations were found in sulci like lunate, transverse occipital, superior and inferior polarsulci.

Table 5: Gyri found on the medial surface

Type of Gyri	Right Occipital lobe		Left Occipital lobe	
	No. of cases found	% age	No. of cases found	% age
Cuneus	30	100	30	100
Lingual	30	100	30	100

Table 6: Gyri found on the infero surface

Type of Gyri	Right Occipital lobe		Left Occipital lobe	
	No. of cases found	% age	No. of cases found	% age
Medial occipito-temporal	30	100	30	100
Lateral occipito-temporal	30	100	30	100

4. DESCRIPTION OF SULCI FOUND IN THE PRESENT STUDY

The lunate sulci were present in 12 (40%) cases on the occipital lobes of right cerebral hemispheres and 14 (46.7%) cases of occipital lobes of left cerebral hemispheres. Out of 60 occipital lobes in 24 (40%) cases of occipital lobes of cerebral hemispheres the lunate sulci were bilaterally present and in 2 (3.33%) cases of left occipital lobes the lunate sulci were unilaterally present. In 26 (43.33%) cases of occipital lobes of right and left cerebral hemispheres of the human brains the lunate sulci were found to be present and in 34 (56.67%) cases of occipital lobes of right and left hemispheres of the brains the lunate sulci were found to be absent so it is not symmetrically present in all the cases of occipital lobes of cerebral hemispheres of human brains (Table - I).

The transverse occipital sulci were present in all the 30 (100%) cases of the occipital lobes of right cerebral hemispheres and on the occipital lobes of left cerebral hemispheres these were found in 26 (86.7%) of cases. In 4 (13.3%) cases it was absent on occipital lobes of left cerebral hemispheres of human brains. Out of 60 occipital lobes, in 56 (93.33%) cases these sulci were bilaterally present in 4 (6.57%) cases of left occipital lobes these sulci were unilaterally absent (Table - I).

The superior polar sulci were present in 12 (40%) cases of occipital lobes of right cerebral hemispheres and in 14 (46.67%) cases of occipital lobes of left cerebral hemispheres. Out of 60 occipital lobes of right and left cerebral hemispheres in 26 (43.33%) cases these sulci were present and in 34 (56.67%) cases of occipital lobes of cerebral hemispheres these sulci were absent.

Out of 60 cases of occipital lobes in 12 (20%) cases of occipital lobes of cerebral hemispheres the sulci were bilaterally present and in 2 (3.33%) cases these were unilaterally absent on occipital lobes of right cerebral hemispheres (Table - I).

The inferior polar sulci were present in 12 (40%) cases of occipital lobes of right hemispheres and in 14 (46.67%) cases of occipital lobes of left cerebral hemispheres these sulci were present. Out of 60 occipital lobes of right and left cerebral hemispheres in 26 (43.33%) cases these sulci were present and in 34 (56.67%) cases of occipital lobes of cerebral hemispheres these sulci were absent. Out of 60 cases of occipital lobes in 12 (20%) cases of occipital lobes of cerebral hemispheres the sulci were bilaterally present and in 2 (3.33%) cases these were unilaterally absent on occipital lobes of right cerebral hemispheres (Table - I).

The present study shows that the lunate, transverse occipital, superior polar and inferior polar sulci are not constantly present in all the occipital lobes of cerebral hemispheres of human brain, they are variable in number and shape and size. They may or may not be present in every occipital lobe of cerebral hemisphere of human brain symmetrically.

Description of Gyri found in the present study: -

Almost all the gyri were found to be present on the 60 occipital lobes of right and left cerebral hemispheres of human brains except the two gyri which are variable in presence (Table - IV).

The arcus parieto-occipitalis gyri were present in 28 (46.67%) cases of occipital lobes of both right and left cerebral hemispheres of human brains. Out of 60 cases of occipital lobes of cerebral hemispheres 56 (93.33%) cases of occipital lobes were having bilateral presence of these gyri and in 4 (6.67%) cases of occipital lobes the arcus parieto-occipitalis was found to be absent (Table - IV).

The gyrus descendens gyri were present in 12 (40%) cases of occipital lobes of right cerebral hemispheres and in 14 (46.7%) cases on occipital lobes of left hemispheres. Out of 60 occipital lobes of cerebral hemispheres in 26 (43.33%) cases of occipital lobes, these gyri were present bilaterally and in 34 (56.67%) cases of occipital lobes these gyri were absent, out of which in 24 (40%) cases were having bilaterally presence of the gyri and in 2 (3.33%) cases were having unilaterally presence of these gyri on left occipital lobes of cerebral hemispheres of human brains (Table - IV).

The present study shows that the arcus parieto-occipitalis and gyrus descendens gyri are not constantly present in all the occipital lobes, they may or may not be present in all the occipital lobes of cerebral hemispheres symmetrically.

Table 7: Occipital grooves found in occipital lobes

Type of Grooves	Right Occipital lobe		Left Occipital lobe	
	No. of cases found	% age	No. of cases found	% age
Occipital groove	26	86.7	9	30

In the present study the occipital grooves on right occipital poles were larger and prominent as compared to the left occipital grooves. Out of 60 occipital pole 35 (58.33%) cases of occipital lobes were having the occipital grooves. 26 (43.33%) cases were of right side and 9 (15%) cases were of left side. These grooves on the occipital poles were made by the venous sinuses. On the right side of the occipital lobes the grooves were made by right transverse sinus which is made by the superior sagittal sinus and the left transverse sinus is made by the straight sinus which turns towards the left to form the left occipital groove which is smaller in size.

Discussion: -

The great number and diversity of brain functions were achieved by increasing the surface area of cerebral cortex. Such fissuring is maintained increasing the functional modules of the brain without increasing the size of cerebrum beyond a biologically feasible limits. Despite their anatomic and functional significance, even the gyri that consistently appear in all normal anatomies exhibit pronounced variability in size and configuration. In the present study lot of variations were noticed within the normal anatomy.

The position of the lunate sulcus marks the posterior end of the calcarine sulcus (Velmurugan et al. 1990)¹³. Joshi et al. (2014)¹⁴ described in their study that the calcarine sulcus did not reach the occipital pole in 8 specimens (24.1%) and

hence was not limited by the lunate sulcus on the superolateral surface. Allen et al. (2006)¹⁰ described that the presence of the lunate sulcus on the occipital lobe was variable. The presence of lunate sulcus in the right and the left cerebral hemispheres were in the frequency of 26.4% and 32.7% respectively. Ono et al. (1990)¹¹ described that the lunate sulcus was present in 60% of the right and 64% of the left hemispheres. In the present study the lunate sulcus was observed to be bilaterally present in 12 (40%) cases. It was unilaterally present in 2 (6.67%) cases on left occipital lobes of cerebral hemispheres of brains.

The transverse occipital sulcus as described by Williams et al. (2000)³² is present in all the occipital lobes of cerebral hemispheres of human brains. In the present study it was found in all the 30 (100%) occipital lobes of right side cerebral hemispheres and in the left occipital lobes 26 (86.7%) lobes were having the transverse occipital sulcus and it was absent in 4 (13.3%) cases of occipital lobes on left hemispheres. The present study shows that out of 60 cases of occipital lobes 56 (93.33%) cases were having transverse occipital sulci and in 4 (6.67%) cases of occipital lobes the transverse occipital sulci were unilaterally absent on left occipital lobes of cerebral hemispheres of human brains.

In the present study both the superior polar and inferior polar sulci were equally present and absent in occipital lobes of cerebral hemispheres. The superior polar and inferior polar were defined by Williams (2000)³² that these sulci ascend and descend from the ends of the lunate sulcus. In the present study the superior polar and inferior polar sulci which are related with lunate sulcus also go with the same pattern as the lunate is. The superior polar and inferior polar sulci were present in 12 (40%) cases of occipital lobes of left cerebral hemispheres and 14 (43.3%) cases of left occipital lobes. It was found that in 12 (40%) these sulci were present bilaterally and in 2 (6.67%) cases these sulci were present unilaterally in left occipital lobes of hemispheres.

The arcus parieto-occipitalis gyrus was found to be present in 28 (93.3%) cases of both right and left occipital lobes of hemispheres, it was bilateral symmetrically absent in 2 (6.7%) cases of both right and left occipital lobes of cerebral hemispheres.

The gyrus descendens was present in 12 (40%) cases of right occipital lobes and in 14 (46.7%) cases of left occipital lobes of cerebral hemispheres. It was bilaterally present in 12 (40%) and in 2 (6.7%) it was unilaterally present on left occipital lobes.

Although the grooves were visible on both occipital lobes, the right groove was more prominent and lay just lateral to the occipital pole. In the remaining brains the groove were made by the venous sinuses and were farther away from the occipital poles running first on the medial and then on the inferior surface (Bisaria – 1984)³³. The occipital grooves which were present on occipital poles of occipital lobes of cerebral hemispheres of the brains were formed by the superior sagittal venous sinus on the right side and on the

left side the grooves are formed by the straight sinus on occipital pole. In the present study the occipital grooves were found to be present in 26 (86.7%) right occipital poles and in 9 (30%) left occipital poles. There was no symmetry in the presence of these grooves on the occipital lobes of cerebral hemispheres of human brains due to change in mode of formation of right and left occipital grooves.

In the present study the parieto-occipital, lateral occipital, calcarine, collateral and occipito-temporal sulci were present in all the 60 (100%) occipital lobes of right and left cerebral hemispheres. There were some variations in their shape, size, and extent otherwise all occipital lobes showed the bilateral symmetry. The superior occipital inferior occipital cuneate, lingual, medial occipito-temporal, and lateral occipito-temporal gyri were also present in all 60 (100%) occipital lobes of cerebral hemispheres of the human brains. They showed slight variations in their shape size and pattern of interruptions; otherwise their presence was bilateral symmetrical.

According to Holloway (1983)³⁴ shift in placement in sulci throughout brain evolution reflects in underlying neural organization. It has been suggested by Wilkin and Wakefield (1995)³⁵ that the enlarging brain deform in exactly those locations where field of distinct cytoarchitectonic structure and organization come into close proximity. The pattern of primary sulci appear as a result of deformational energy particularly concentrated in an architectonic boundary.

5. CONCLUSION

The occipital lobe of cerebral hemisphere of human brain is the posterior most lobe of the brain. This lobe is having the center for the vision because visual cortex lies in this region. It is found in the present study that all the human brains are not having all the sulci and gyri on every brain. The sulci and gyri may or may not be present every brain. The anatomical knowledge of the presence of sulci and gyri may be important for neurosurgeons and general surgeons for operating on the posterior lobe tumors. The knowledge of morphological relations of this lobe and the identification of its relationship facilitates the approach to subcortical lesions and permit safer access to deep structures. It is also important for radiologists for their diagnosis while reading the MRI and may be aware of sulci and gyri variations in their clinical practice. The present study will be helpful to anatomists for their study, neurosurgeons and general surgeons in their neurosurgery and radiologists in their clinical radiodiagnosis.

6. REFERENCES

1. Standring, S. Gray's Anatomy. The anatomical basis of clinical practice. 39th edition, chapter – the cerebrum. Elsevier- Churchill Livingstone, New York; 2005; page: 403.

2. Sinnatamby, CS. Last's Anatomy. Regional and Applied. 12th edition, chapter 7 – the central nervous system. Churchill Livingstone Elsevier; Edinburgh, London, New York, Oxford, Philadelphia, St. Louis, Sydney, Toronto; 2011; page: 456 – 458.
3. Smith, EG. Studies in the morphology of the human brain with special reference to that of the Egyptians. Cited by Connolly CJ. In: External Morphology of the primate brain. Charles C Thomas. Springfield Publisher, Illinois, USA. 1st edition. 1903; Page: 273 – 392.
4. Connolly, CJ. External Morphology of the primate brain. 1st edition, Charles C Thomas. Springfield Publisher, Illinois, USA; 1950; page: 350 – 361.
5. FitzGerald, MJT; Gruener, G; Mtui, E. Clinical Neuroanatomy and Neuroscience. 6th edition, chapter-2, Cerebral topography. Elsevier Saunders Publishers; London, New York; 2012; page 8.
6. Snell, RS. Clinical Neuroanatomy. 7th edition, chapter-7 the cerebrum. Wolters Kluwer/ Lippincott Williams Wilkins. New Delhi, Philadelphia, Baltimore, New York, London, Buenos Aires, Hong Kong, Sydney, Tokyo; 2010; page 260 – 262.
7. Romans, GJ. Cunningham's Text Book of Anatomy. 12th edition, chapter- the central nervous system. Oxford University Press, Oxford, New York, Toronto; 1995; page: 665 – 667.
8. Dutta, AK; Prasad, VN. Essentials of Neuroanatomy. 3rd edition, chapter fore brain. Current Books International Publisher, 60 Lenin Sarance, Kolkata; 2005; page: 44.
9. Iaria, G and Petrides, M. Occipital sulci of the Human Brain: Variability and Probability Maps. Journal of Comp Neurology 2007; 501: 243 – 259.
10. Allen, J; Bruss, J; Damasio, H. Looking for the lunate sulcus: A magnetic resonance imaging study in modern humans. Anat Rec A DiscovMol Cell EvolBiol; 2006; 208: 867 – 876.
11. Ono, M; Kubik, S; Abernathey, CD. Atlas of the cerebral sulci, its medical and surgical aspect. Thieme Medical Publishers, New York; 1990; page: 62 – 74.
12. Ananth, C. Position of the lunate sulcus. A morphometric study, Anatomical Adjuncts; 1998; 2 (4): 33 – 40.
13. Velmurugan, M; Bhaskaralingam, S; Ravi, C. A study on the position of the lunate sulcus. Anatomical Adjuncts; 1990; 1 (9): 89.
14. Joshi, S; Kommuru, H; Balasubramaniam, B; Prabhakaran, E. Gross anatomical features of calcarine sulcus. Int J ofScientific research 2014; 3 (5): 479 – 481.
15. Falk's, D. External Neuroanatomy of Old World Monkeys (Cercopithecoidea). ContribuPrimatol; 1978; 15: 1.
16. Falk's, D. Humid Brain Evolution: The approach from paleneurology. Year book PhysAnthropol; 1980; 73: 93.
17. Dart, RA. Relationship of brain size and brain pattern to human status. S Afr JSci 1956; 21:23.
18. Broom, R; and Schepers, GWH. South African Fossils Ape – Man. The Australopithecinae. Transvaal MusMem; 1946; 2: 1.
19. Clark, WEL; Cooper, D; Zuckerman, S. The endocranial cast of the chimpanzee. J RaAnthrop Inst 1936; 6: 249.
20. Flores, LP. Occipital Lobe Morphological Anatomy. ArqNeuro-psiquiatr; 2002; 60: (3-A): 566 – 571.
21. Carpenter, MB. Core Text book of Neuroanatomy. 4th edition. Williams and Wilkins, Baltimore; 1991; page: 23 – 54.
22. Seeger, W. Atlas of topographical anatomy of the brain and surrounding structures for Neurosurgeons, Neurodiagnostics, Neuropathologists. Wien: Spriegel; 1978; page: 340 – 349.
23. Ribas, GC. The cerebral sulci and gyri. Neurosurg Focus; 2010; 28 (2): 12 – 13.
24. Tallinen, T; Chung, JY; Biggins, JS; Mahadevan, L.. Gyrfication from constrained cortical expansion. Proceedings of the National Academy of Science of U.S.A; 2014; 111 (5): 12667 – 12672.
25. Brash, JC. Cunningham's Manual of Practical Anatomy. 12th edition, Volume– 3, chapter- the cerebrum. Oxford University Press. London, New York, Toronto; 1960; page: 421 – 442.
26. Chusid, JG. The Brain. In: Correlative Neuroanatomy and functional Neurology. 16th edition. Lange Medical Publishers, London; 1976; page 1 – 6.
27. Hamilton, WJ. Cerebral Cortex. In: The text book of Human Anatomy. 2nd edition. MacMillan Press Ltd. London, Basin stoke, New York; 1976; page: 558 – 584.
28. Kiernan, JA. Topography of the cerebral hemisphere. In: Barr's The Human Nervous System. 7th Edition. Lippincott – Raven Publishers, Philadelphia; 1998; page: 284 – 285.
29. Jones, W. The cerebrum. In: Buchanan's Manual of Anatomy. 8th edition. BT Cox London; 1949; page: 1343 – 1354.
30. Romans, GJ. Cunningham's Manual of Practical Anatomy, 15th edition, volume 3 chapter- the cerebrum. Oxford University Press, Oxford, New York, Tokyo; 20112; page: 249 – 258.
31. Williams, PL; Warwick, R; Dyson, M; Bannister, LH. Gray's Anatomy. 37th edition, chapter- the Telencephalon. Churchill Livingstone, Edinburgh, London, Melbourne and New York; 1989; page: 1021 – 1028.
32. Williams, PL; Bannister, LH; Berry, MM; et al. Gray's Anatomy. In: Telencephalon: Surfaces of the cerebrum. 38th edition. Churchill Livingstone, New York; 2000; page: 1107 – 1115.
33. Bisaria, KK. Anatomical note: grooves on the occipital poles of Indian brains. J Anat 1984; 139: 579 – 582.

Int J Pharma Res Health Sci. 2016; 4 (6): 1454-1461

34. Holloway, RL. Human Brain Evolution: A search for units, models and synthesis. *Canad J Anthropol* 1984; 3: 215.
35. Wilkin, WK; Wakefield, J. *Brain Evolution and Neurolinguistic Preconditions*. 35th edition. Churchill Livingstone, New York; 1995; page: 920 – 929.

Conflict of Interest: None

Source of Funding: Nil